

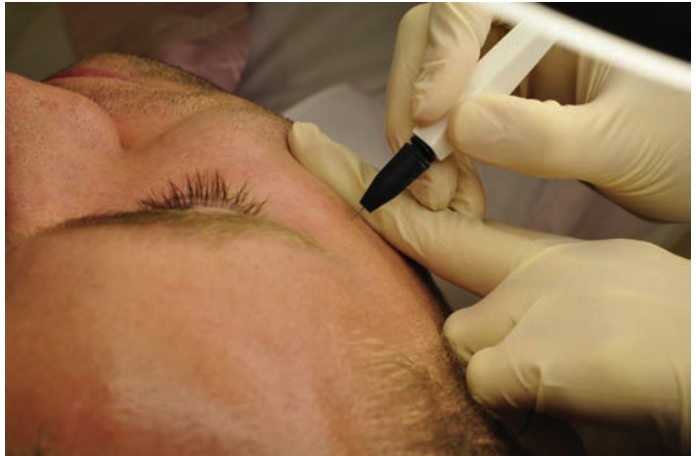Advanced Electrolysis



Advanced Electrolysis

In the UK, most people think that electrolysis is only used for hair-removal. However, a wide range of skin related problems can be treated using advanced techniques of electrolysis – known as Advanced Electrolysis.

Using a magnifying lamp, a minute sterile needle is introduced either alongside or into the area to be treated. When in position, a tiny energy current is discharged precisely at the relevant point to have the maximum effect. It is a safe, comfortable and effective treatment which is becoming increasingly popular for treating skin problems in both women and men.



What can be treated?

All of our Clinicians who perform Advanced Electrolysis have attended specialist, professional training courses and are fully accredited to treat the following conditions:

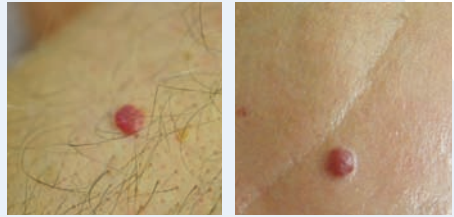- Facial Thread Veins
- Spider Naevi
- Blood Spots (Campbell de Morgan spots)
- Skin Tags
- Warts
- Verruca
- Milia
- Dermatitis Papulosa Nigra
- Xanthelasma
- Syringoma
- Sebaceous Cysts
- Seborrhoeic Keratosis
- Age Spots

How long will the treatment take?

The time taken to treat any of these conditions will depend on the size, number and nature of the problem. In addition, the clients' personal expectations can also alter how much is performed at any one session. It is important that the area treated is not 'overworked', therefore treatments are spaced out at regular intervals. The Absolute Aesthetics Clinicians will discuss these issues at the initial consultation and will keep the patient informed regarding the progress with ongoing consultations at the start of the treatments.

Spider Naevus/Blood Spots (Campbell de Morgan spots)

Spider Naevus is a central, dilated blood vessel with capillaries radiating away from the centre (thought to be caused by squeezing in some cases). They are very often found in isolation or grouped together in areas such as on the cheeks.

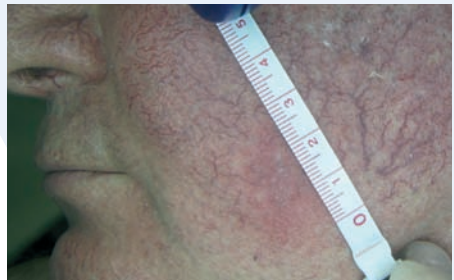

Campbell de Morgan spots

Blood spots are bright red, vascular blemishes which develop on the body (very often on the trunk or torso) and develop naturally as the skin ages and cell renewal slows down. They are properly known as Campbell de Morgan spots.

Facial Thread Veins

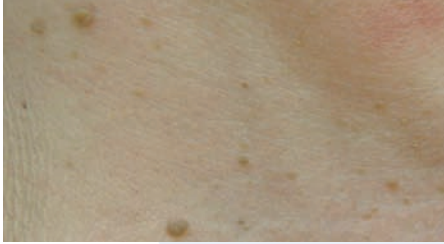These are conditions that are most commonly found on the face (particularly around the nose) and legs. They can be caused by many factors, including ageing, pregnancy, harsh weather and smoking. The needle is put on to the vein and then an electrical current is released. The current will cauterize the vein, killing the vessel wall and causing the blood to coagulate, come to the surface and then disappear.



Thread veins

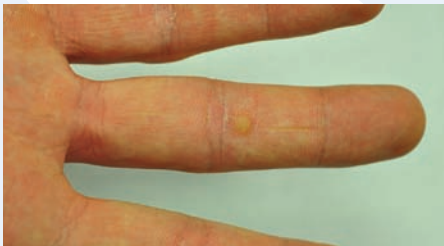
Skin Tags/Warts/Milia/Dermatosis Papulosa Nigra/Verruca

Skin tags are very common and normally found around the bust, neck or areas of friction such as the underarm. They are harmless but can be both unsightly and irritating.



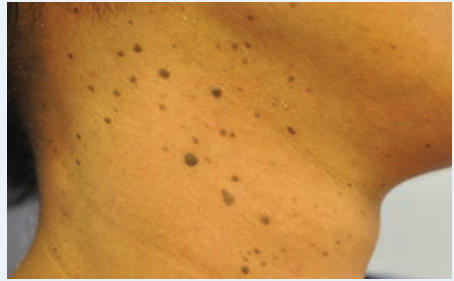
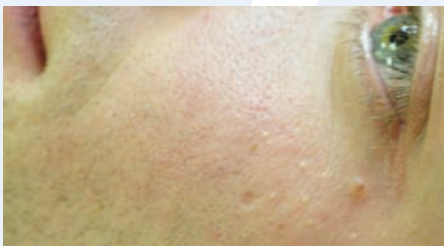Skin tags

There are various types of warts, including common, plane, seborrhoeic (more common with age) and verruca which can develop individually or in groups. All types of warts are benign and can be treated successfully.



Common wart

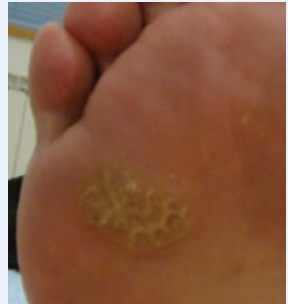Milia are very small, white, hard keratin-filled cysts which lie superficially under the surface of the skin, commonly around the eye area.



Dermatosis Papulosa Nigra

Dermatosis Papulosa Nigra is a very common disorder which develops, during adolescence on black skin, causing round shaped, black papules on the cheeks neck and chest.

Verrucas develop on the soles of the feet and are slightly raised and circular in shape. They can sometimes form small clusters which are called 'mosaic warts'.



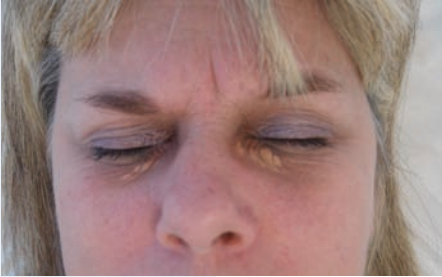If left untreated, they can persist for several years and become quite painful.

All of these conditions are benign and treated by gently inserting the needle into the area and then releasing the electrical current which kills it from the inside, allowing it to dry up and fall off.

Xanthelasma/Syringoma/Sebaceous Cysts

Xanthelasma is a condition which is presented as a collection of cholesterol usually found on or beneath the eyelids. Although not harmful or painful, these growths may be cosmetically unattractive and can be removed.

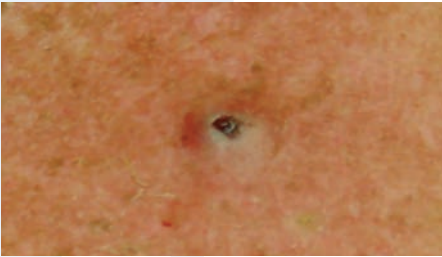
A Syringoma is a non-cancerous, benign bump usually found on the upper cheeks, lower eyelids, armpits, chest, abdomen or forehead.



Xanthelasma

Completely harmless, it is caused by the overgrowth of cells from the sweat glands.

Sebaceous Cysts are small lumps or bumps found just underneath the surface of the skin.

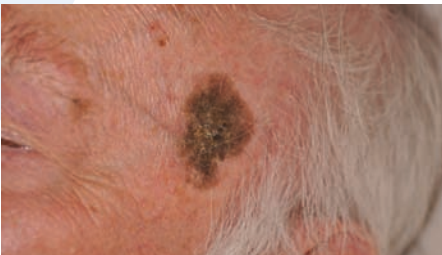

Sebaceous Cyst

They are benign and are closed 'sacs' that contain a substance called Sebum which is a 'cheesy' looking protein that often has an unpleasant odour.

Seborrheic Keratosis

A Seborrheic Keratosis usually appears on the skin of adults as a brown crusty spot or lump.



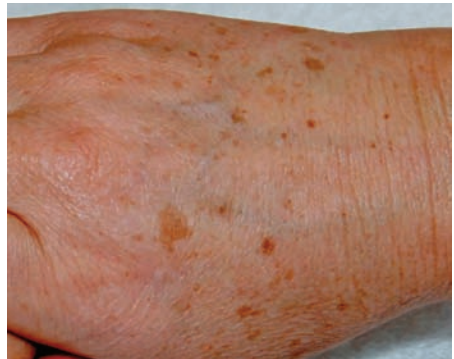Although they are usually quite distinctive, being dark brown with a hard crust, they can occasionally be more flesh coloured or much darker, almost black.

Seborrheic Keratoses can vary a great deal in their shape. Often they are round but they can also appear oval, or sometimes a more irregular shape. Although they can occasionally occur singly, more often than not, you may find several or sometimes a great many of them.

Age Spots

Age Spots are usually caused by exposure to the sun and generally appear on areas such as the hands, face, shoulders and arms.

They are superficial marks on the surface of the skin that are brown or black in colour and are sometimes also known as 'liver spots'.



If you would like to know more about Advanced Electrolysis at Absolute Aesthetics, please look at the website:

www.absoluteaesthetics.co.uk

or contact us on:

info@absoluteaesthetics.co.uk

or Tel: 01483 477 189

01483 477 189

info@absoluteaesthetics.co.uk • www.absoluteaesthetics.co.uk

Absolute Aesthetics is a division of The Whiteley Clinic
1 Stirling House • Stirling Road • Guildford • Surrey • GU2 7RF